

## Protemp™ Crown Temporization Material

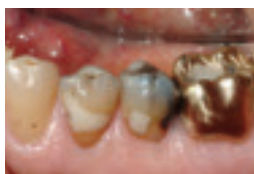### Clinical Case Studies

#### Introduction

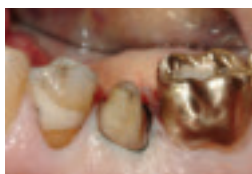Protemp™ Crown Temporization Material from 3M ESPE is the world's first preformed, malleable temporary crown, providing speed and simplicity in temporization like never before. With this revolutionary light-curable material and time-saving technique, dental professionals can quickly trim and adapt a single-unit composite crown to deliver a strong and esthetic custom fit in four minutes or less. Indicated for temporary posterior crowns, Protemp Crown offers precision fit and excellent strength. No impression or matrix is needed, eliminating mess and clean-up while increasing productivity and delivering strong and esthetic results.

#### Clinical Case 1: Restoration of Posterior Bicuspid Crown

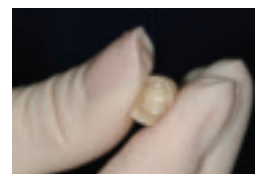
Clinical Case by Dr. Don Erickson, Saint Paul, Minnesota



Initial situation: Decay, fractured buccal cusp and unsupported lingual cusp on tooth No. 20, buccal view.



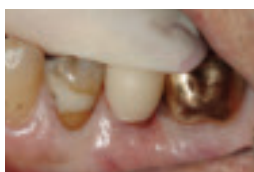Tooth prep prior to placement of Protemp™ Crown Temporization Material, buccal view.



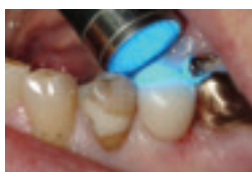Roll Protemp™ Crown Temporization Material between gloved fingers to soften.



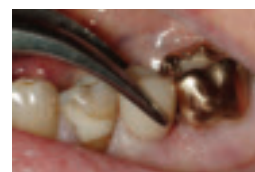Trim Protemp™ Crown Temporization Material to obtain proper height.



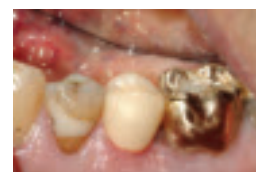Placement of Protemp™ Crown Temporization Material prep, close to final position.



Tack cure of lingual surface.



Protemp™ Crown Temporization Material removed after initial tack cure.



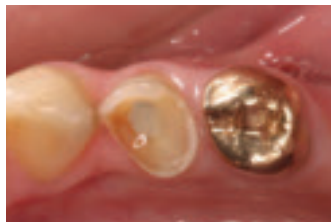Cementation of Protemp™ Crown Temporization Material in patient's mouth using temporary cement.

**Initial situation:** Recurrent decay on the distal surface of tooth No. 20. Due to the fractured buccal cusp and weak unsupported lingual cusp, tooth No. 20 required full crown restoration. The existing crown was removed and an interim temporary restoration was placed using Protemp™ Crown Temporization Material, to be followed by a permanent PFM crown.

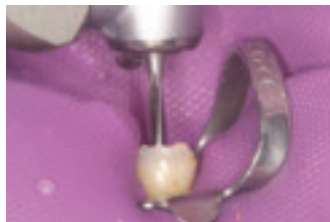**Treatment plan:** Old amalgam and undercuts were filled in with F2000 Compomer Restorative and the surface was finished with a tapered carbide bur. Protemp Crown was rolled between gloved fingers for approximately one minute to soften it and the gingival margin was trimmed to the approximate length of the preparation. Protemp Crown was placed onto the prepared tooth and shaped to establish a precise fit. The buccal and lingual margins were adapted and occlusal adjustments made, and the buccal, lingual and occlusal surfaces were each tack cured for 2-3 seconds. Protemp Crown was removed and all surfaces of the crown were light cured outside of the mouth for a total of 60 seconds. The cured crown was fitted onto the preparation, finished and polished using a composite polishing disc and cemented with temporary cement.

## Clinical Case 2: Emergency Restoration of Fractured Bicuspid


Clinical Case by Dr. Christopher D. Ramsey, Jupiter, Florida



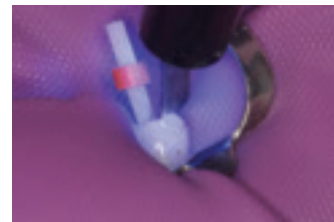
Initial situation: Root canal on fractured tooth No. 21.



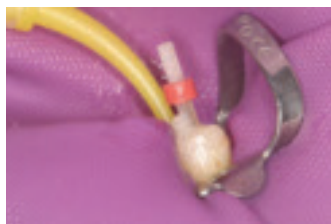
Drill used to widen and shape the canal.



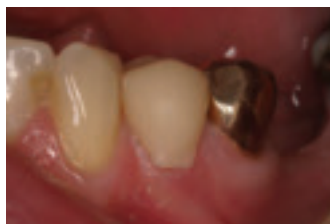Injecting RelyX™ Unicem Self-Adhesive Universal Resin Cement into canal.



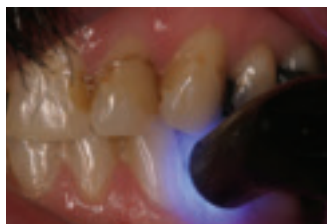Corresponding RelyX™ Fiber Post placed into canal and light cure of cement.



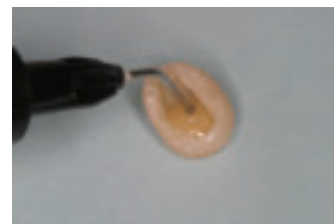Crown build-up completed with direct restorative material.



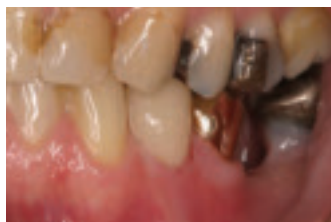Protemp™ Crown Temporization Material placed onto the preparation and adapted.



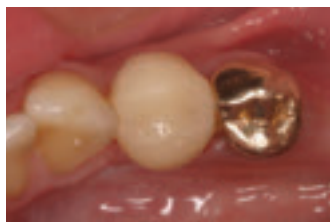Tack cure of buccal surface.



Crown lined with Filtek™ Supreme Plus Flowable Restorative.



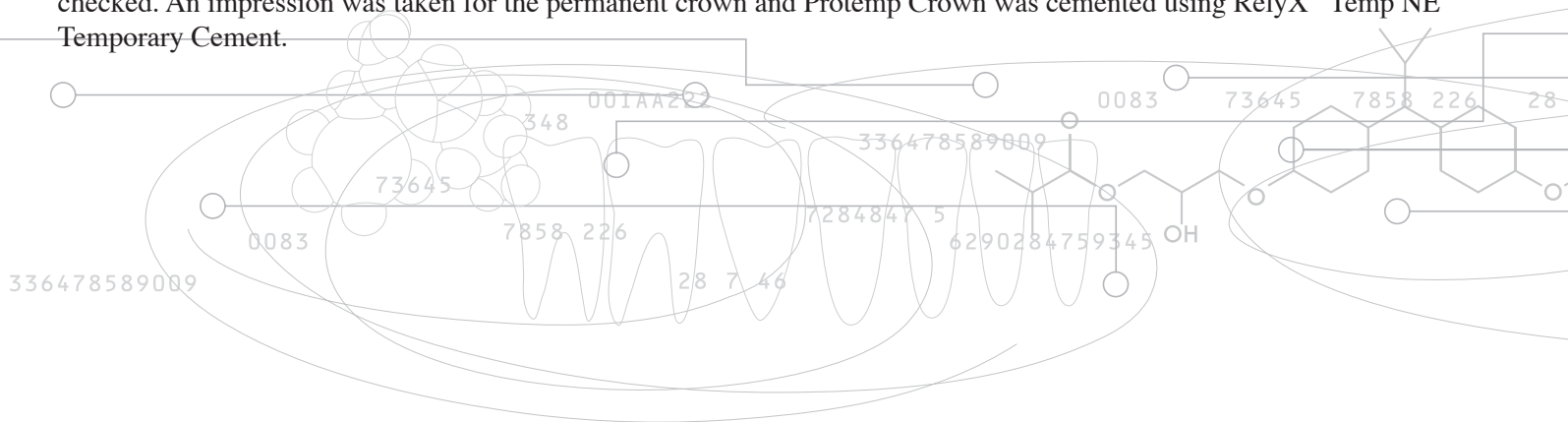
Occlusion checked with crown in place.



Placement of Protent™ Crown Temporization Material with temporary cement.

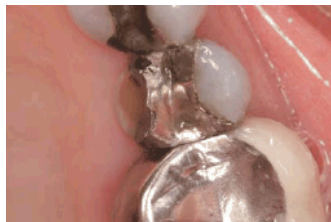**Initial situation:** Root canal on fractured tooth No. 21. Patient in poor dental health required emergency restoration. Provided post, core build-up and Protent Crown while permanent restoration was fabricated.

**Treatment plan:** Patient was anesthetized and a non-latex rubber dam was placed. Space for 1.6mm-diameter RelyX™ Fiber Post was created using corresponding drill and the post was inserted into canal to check the fit. RelyX™ Unicem Self-Adhesive Universal Resin Cement was dispensed into canal using the RelyX™ Unicem Aplicap™ Elongation Tip. RelyX fiber post was placed in the canal and light cured for 40 seconds. Direct restorative material was used to create the crown build-up, followed by a 20-second light cure and trimming of the post. After measuring the mesial-distal width of the preparation, the proper size Protent Crown was removed from the package, trimmed and placed onto the prep. The buccal and lingual margins and proximal contacts were adapted and, as the patient bit down, occlusal fit was established. Buccal, lingual and occlusal surfaces were each tack cured for 2-3 seconds and the crown was removed. The crown was lined with Filtek™ Supreme Plus Flowable Restorative and tack cured. Protent Crown was light cured for 60 seconds and re-seated onto the prep. The margins were finished to obtain a close fit along the gingival margin and occlusal fit re-checked. An impression was taken for the permanent crown and Protent Crown was cemented using RelyX™ Temp NE Temporary Cement.

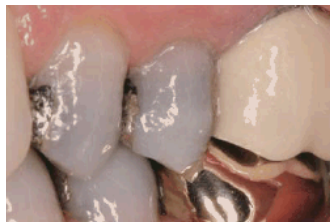

## Clinical Case 3: Preparation and Restoration of Fractured Bicusp

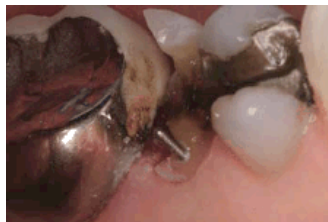Clinical Case by Dr. Robert Margeas, Des Moines, Iowa



Initial situation: Fractured lingual cusp on tooth No. 13.



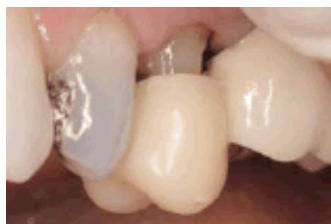Amalgam shine-through.



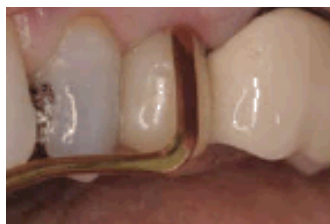Titanium pin placed.



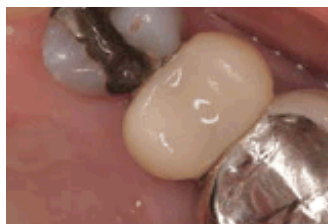Protemp™ Crown Temporization Material shown in protective liner.




Protemp™ Crown Temporization Material placed on preparation.



Protemp™ Crown Temporization Material adapted with composite instrument.



Occlusal view of Protemp™ Crown Temporization Material.



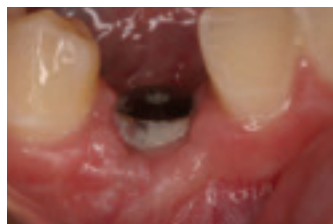Facial view of temporarily cemented Protemp™ Crown Temporization Material.

**Initial situation:** Previously placed large amalgam restoration and a lingual cusp fracture on tooth No. 13. The patient did not like the grayness of the tooth due to amalgam shine-through.

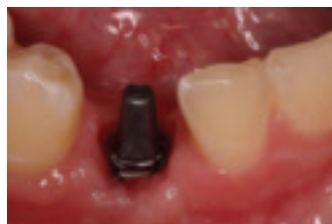**Treatment plan:** Amalgam restoration was removed, along with recurrent decay. A titanium pin was placed where the missing cusp was fractured using an electric slow-speed latch-type handpiece. Following core build-up, the tooth was prepared with a diamond bur and a flame-shaped bur to bevel the prep. The mesial-distal width of the preparation was measured to determine the proper size Protemp Crown. The film was removed and the crown rolled in the fingers to increase malleability. The crown was trimmed following the gingival contour to provide proper height. Protemp Crown was seated onto the abutment; margins and proximal contacts were adapted using the fingers and a composite instrument. The patient bit down to form occlusal contacts and the buccal margin was further adapted, after which the buccal surface was tack cured for 2-3 seconds. The patient opened, lingual margin was adapted; lingual and occlusal surfaces were tack cured for 2-3 seconds. The crown was removed for final curing outside of the mouth for 60 seconds and subsequently finished, trimmed as necessary, polished and cemented with temporary cement.

## Clinical Case 4: Protemp™ Crown Temporization Material Over an Implant Abutment

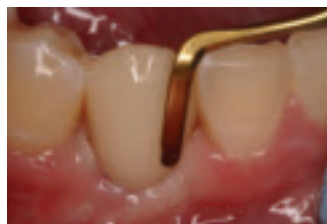Clinical Case by Dr. Robert Margeas, Des Moines, Iowa



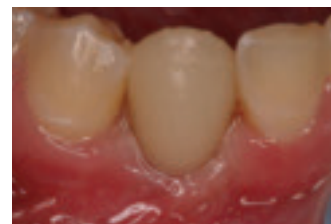Titanium implant with healing abutment.



Implant abutment placed.



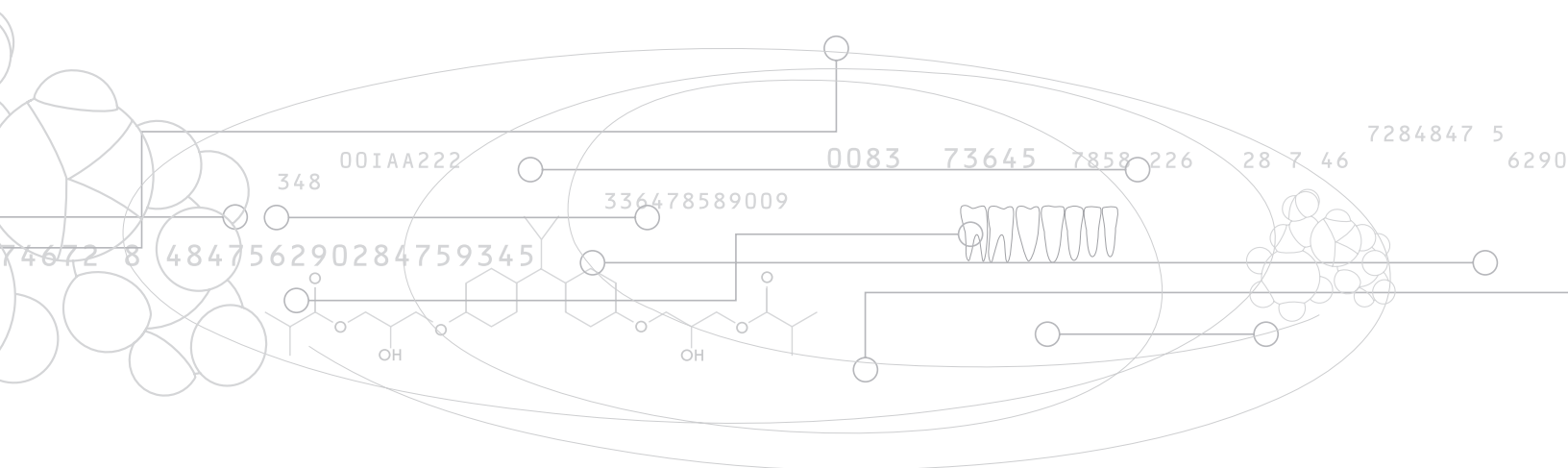
Protemp™ Crown Temporization Material adapted with composite instrument.



Cemented Protemp™ Crown Temporization Material.

**Initial situation:** 19-year-old woman presented with congenitally missing tooth No. 27. An implant was selected as the most fitting method of completing the patient's smile.

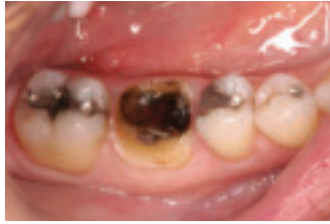**Treatment plan:** A titanium implant was placed and allowed to integrate for a period of three months. An implant abutment was placed and a polyvinyl impression made for fabrication of the final Lava™ Crown. Measurements were taken to determine the appropriate size Protemp™ Crown Temporization Material, and the crown was trimmed to the correct height, following the gingival contour. The crown was placed onto the implant abutment for shaping and adaptation to interproximal contacts. The patient was instructed to gently bite down to establish occlusion and adapt the buccal surface. A composite instrument was used to adapt the buccal margin and adjust the occlusion. The buccal surface was tack cured for 2 seconds, held in place while the lingual margin was adapted, and lingual and occlusal surfaces tack cured for 2 seconds. The crown was then removed from the abutment and cured for 30 seconds using the Elipar™ Freelight 2 LED Curing Light. The crown was finished using Sof-Lex™ Finishing and Polishing Discs and seated with RelyX™ Temp NE Temporary Cement.



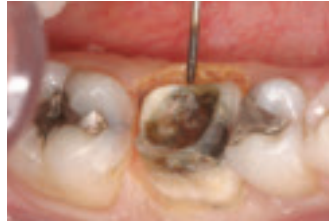

## Clinical Case 5: Emergency Restoration of Dislodged Crown and Core

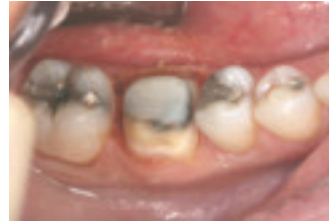Clinical Case by Dr. Christopher Hooper, Virginia Beach, Virginia



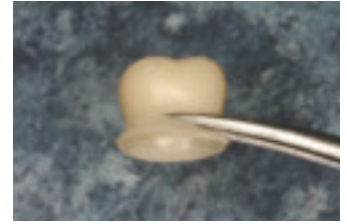
Initial situation: Dislodged crown and build-up on tooth No. 30.



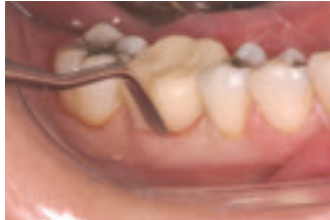Removal of gingival tissue, preserving biologic width.



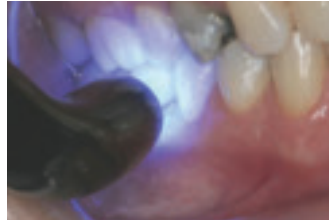Completed tooth preparation and build-up.



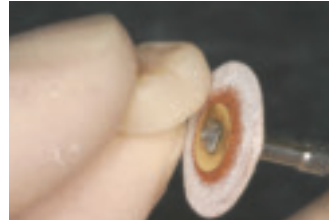
Protemp™ Crown Temporization Material trimmed to approximate height.



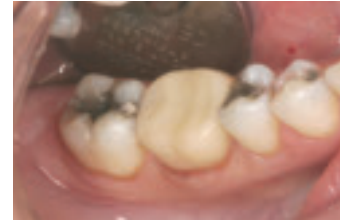Adaption of Protemp™ Crown Temporization Material to the preparation.



Tack cure of buccal surface.



Trim and polish.



Placement of Protemp™ Crown Temporization Material.

**Initial situation:** Dislodged crown and core build-up of tooth No. 30. Initial examination also showed decay present on residual tooth structure. Temporary placement of Protemp™ Crown Temporization Material, followed by a zirconia Lava™ Crown.

**Treatment plan:** Tooth No. 30 was prepared using a chamfer bur and some of the gingival tissue was removed with an electrosurge. After the decay was excavated, Filtek™ Z250 Universal Restorative was used to build up the tooth preparation. The mesial-distal width of the prep was measured to select the proper size Protemp™ Crown Temporization Material. The crown was run under warm water for approximately 15 seconds to soften it, and subsequently trimmed, placed onto the prep and adapted to a precise fit. While the patient bit down, the buccal surface was tack cured using the Elipar™ FreeLight 2 LED Curing Light for 1-2 seconds. The patient opened for 1-2 seconds for curing of the occlusal and lingual surfaces. The crown was removed from the prep using a conventional sickle scaler and all surfaces were light cured outside of the mouth for 60 seconds. The crown was finished and polished prior to final placement.

**3M ESPE**

**Dental Products**

3M Center  
Building 275-2SE-03  
St. Paul, MN 55144-1000

**3M Canada**

Post Office Box 5757  
London, Ontario N6A 4T1  
Canada  
1 (800) 265-1840 ext. 6229



10% post-consumer  
waste paper

Printed in USA  
© 3M 2007

All rights reserved.

3M, ESPE, Filtek, Lava, Protemp, and  
RelyX are trademarks of 3M or 3M  
ESPE AG.

Used under license in Canada.

70-2009-3872-1